



Clinical Overview of Arthritis Conditions

Dr. K. Skeith
June 15, 2006



Disclosure Statement

Dr. K. Skeith

- ◆ Involved in clinical trials sponsored by:
- ◆ Merck, Novartis, Pfizer, Abbott, Sanofi-Aventis

Arthritis Classification

- ◆ **Inflammatory**
 - ◆ **1) Immune-mediated**
 - ◆ **2) Crystalline**
 - ◆ **3) Septic**
- ◆ **Degenerative**

Immune-mediated Arthritis

- ◆ **Rheumatoid Arthritis**
- ◆ **Seronegative spondyloarthropathies**
 - ◆ 1) **Psoriatic arthritis**
 - ◆ 2) **Reactive arthritis (Reiter's syndrome)**
 - ◆ 3) **Ankylosing spondylitis**
 - ◆ 4) **Enteropathic arthritis**
- ◆ **Systemic lupus**

Rheumatoid Arthritis

- ◆ **Pain – varying causes:**
- ◆ **1) Joints – synovitis**
- ◆ **2) Soft tissues – tendinitis, tenosynovitis, bursitis**
- ◆ **3) Nerves – entrapment ie. Carpal tunnel**
- ◆ **4) Vascular structures ie. Vasculitis**
- ◆ **5) Secondary fibromyalgia**
- ◆ **6) Secondary osteoarthritis**

Crystalline Arthritis

- ◆ **Gout**
- ◆ - **uric acid crystals**
- ◆ **Pseudogout (pyrophosphate arthropathy)**
- ◆ - **calcium pyrophosphate dihydrate crystals (CPPD)**

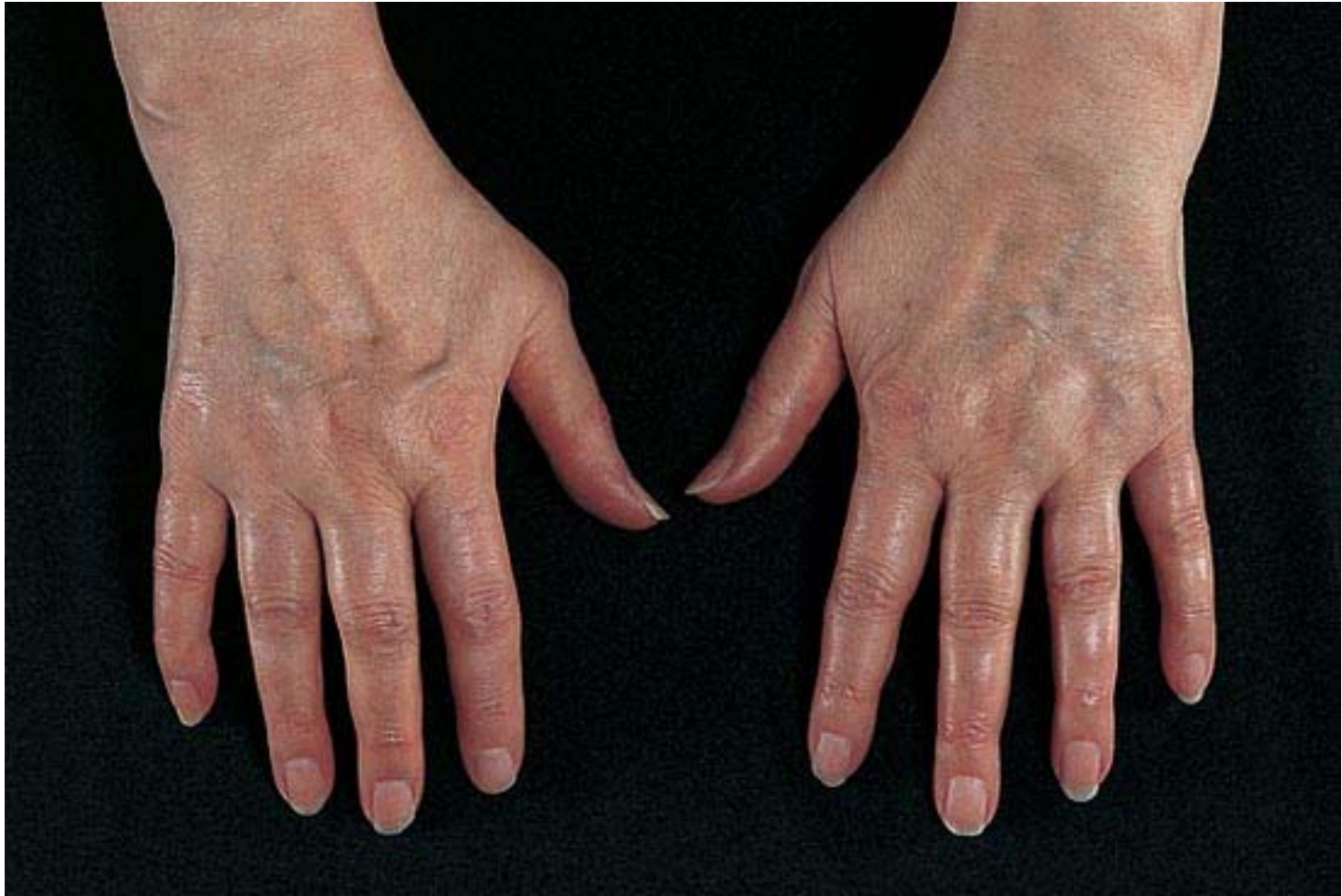Osteoarthritis

- ◆ **Peripheral joints**
- ◆ **Axial (spinal)**
- ◆ **Generalized involvement**
- ◆ **Inflammatory forms ie. CPPD with atypical joint involvement**

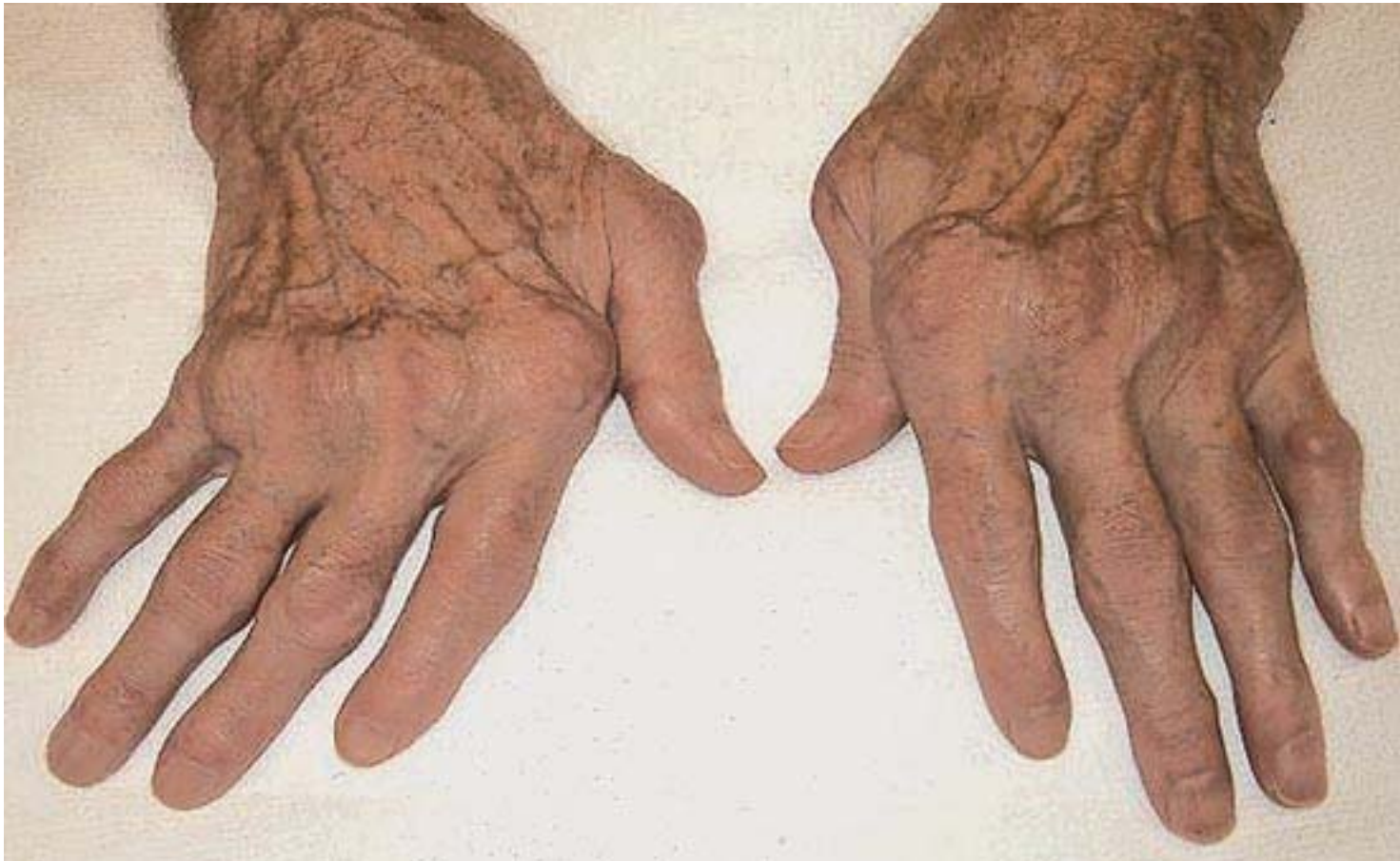Rheumatoid Arthritis

- ◆ **Joint soft tissue swelling**
- ◆ **Redness**
- ◆ **Heat**
- ◆ **Stiffness**
- ◆ **Tenderness**
- ◆ **Painful restricted range of motion**
- ◆ **Systemic features: fatigue, chills, adenopathy**

Rheumatoid Arthritis

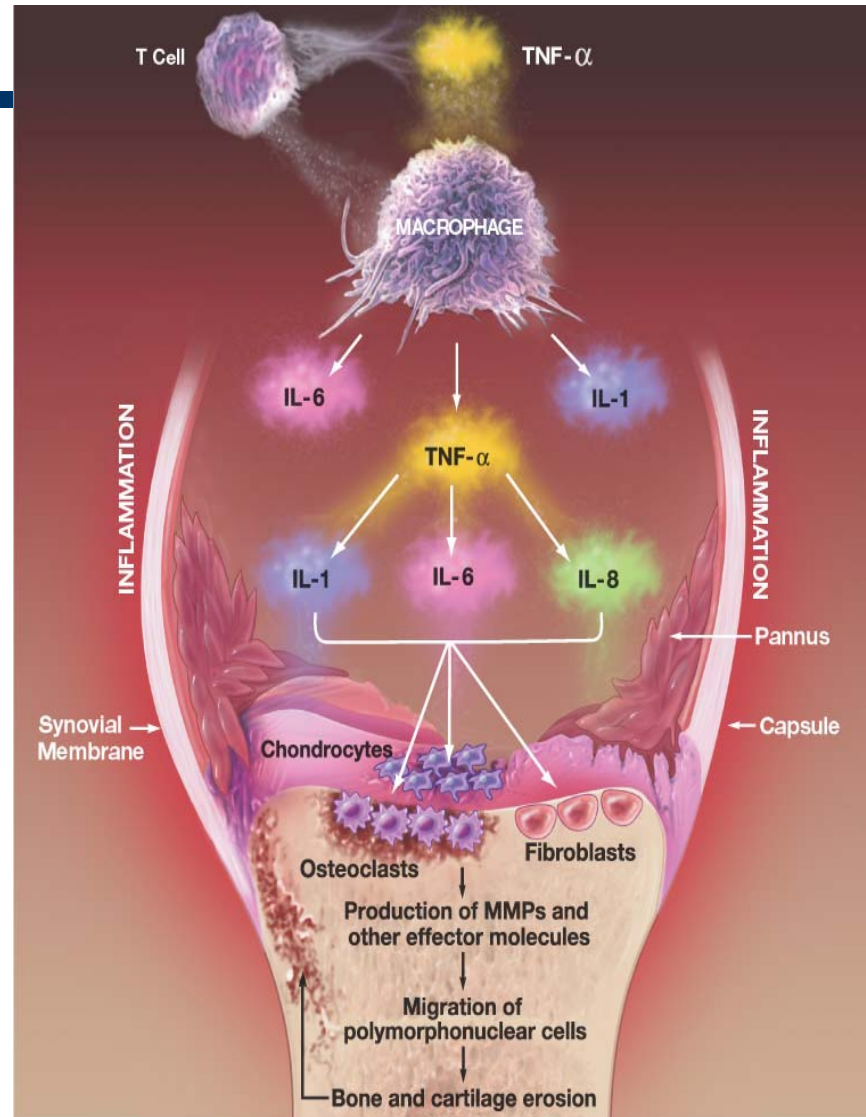


Rheumatoid Arthritis

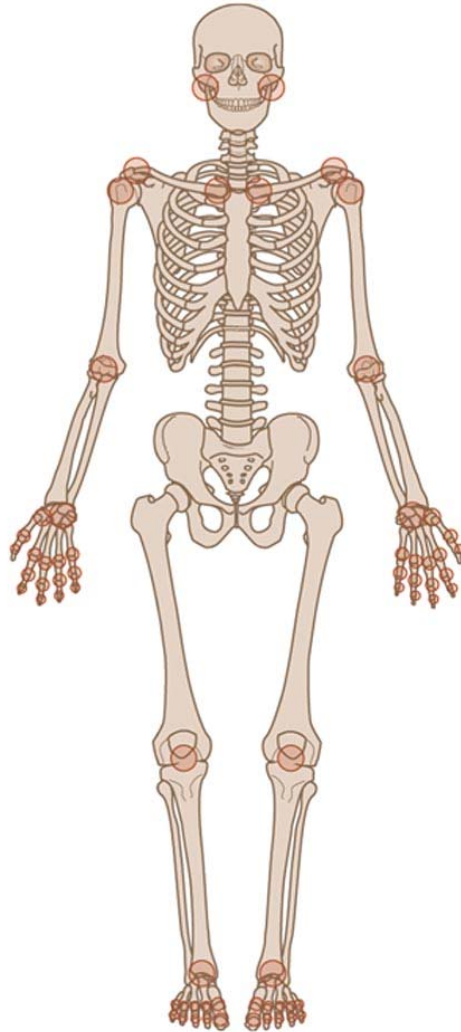


The Immune System in RA

- ◆ RA involves early T-cell activation
 - Subsequent amplification of inflammatory cytokine cascade
- ◆ TNF α is one of the focal cytokines at the apex of RA pathology



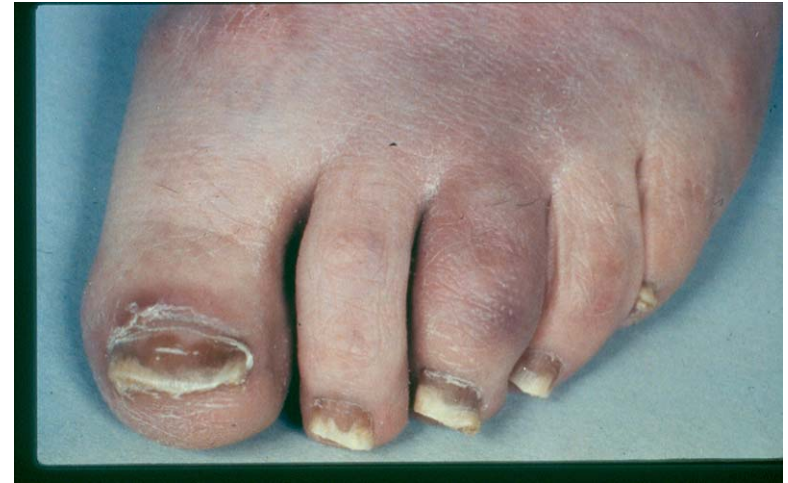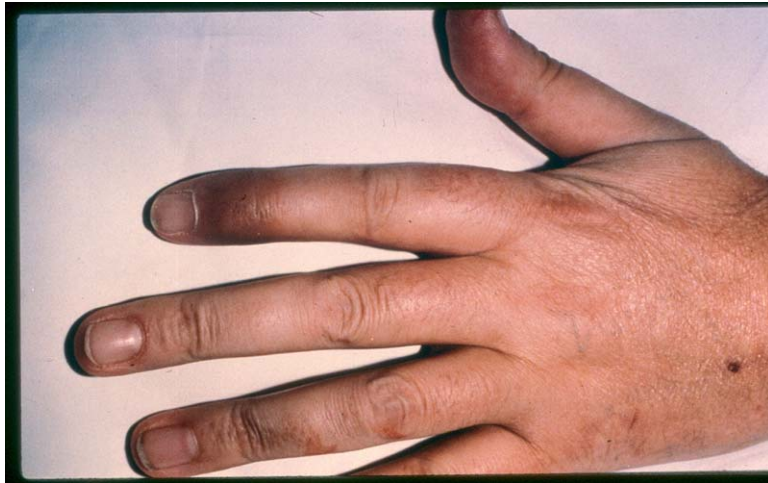Rheumatoid Arthritis



Seronegative Arthritis

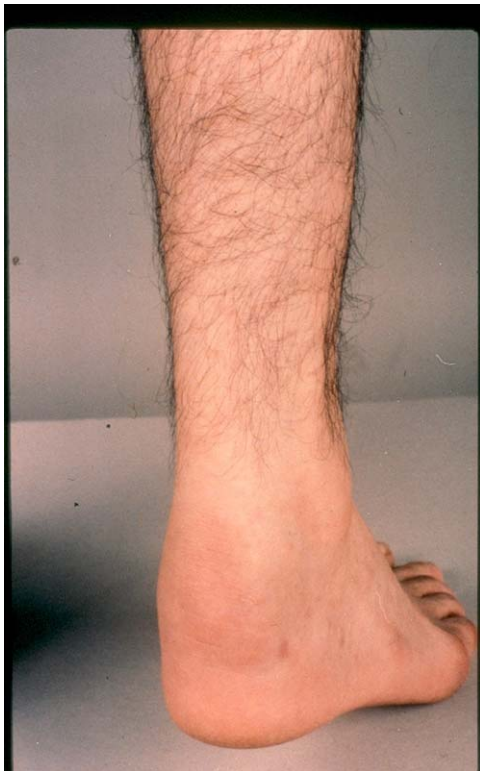- ◆ **Absent rheumatoid factor**
- ◆ **Involvement of spine and sacroiliac joints**
- ◆ **Peripheral Arthritis (usually lower limb)**
- ◆ **Enthesopathy**
- ◆ **Increased incidence of HLA-B27**

Seronegative Arthritis



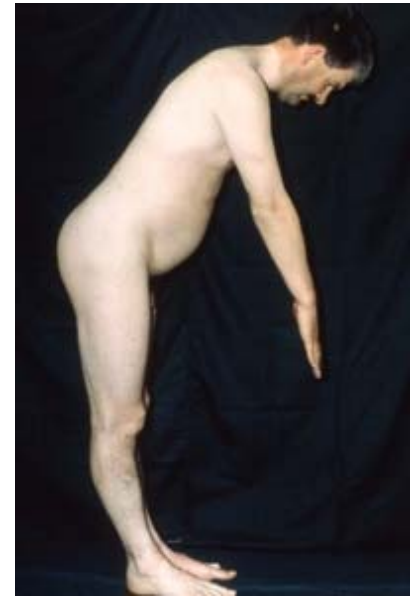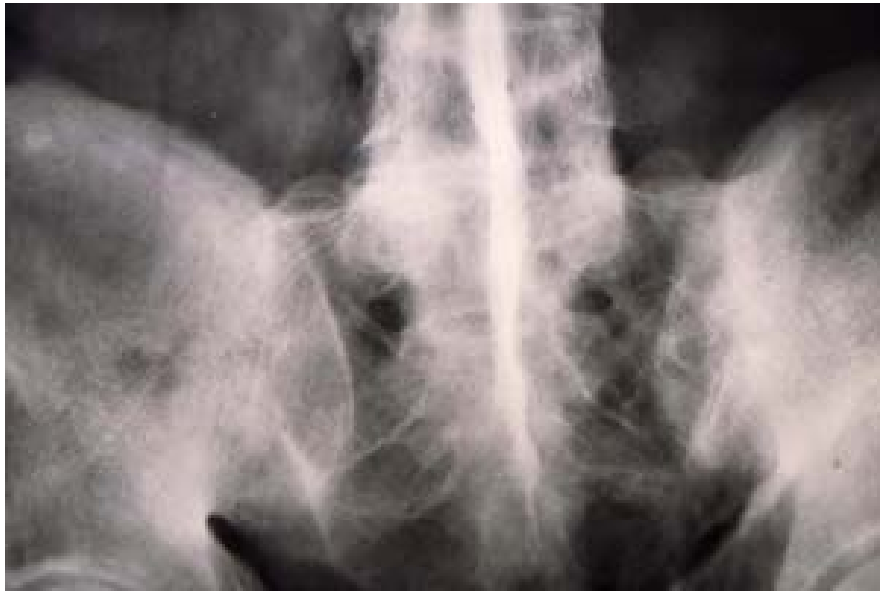Dactylitis, asymmetric involvement typical

Enthesopathy



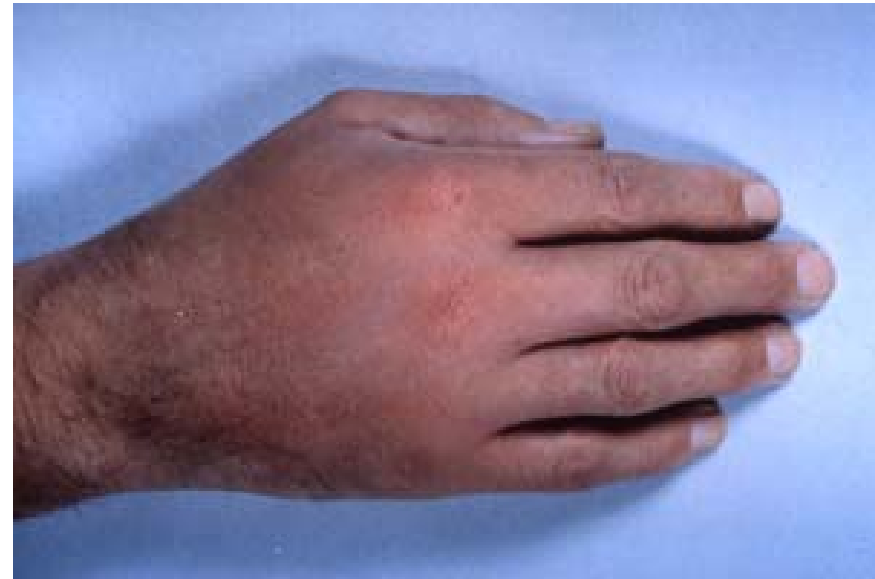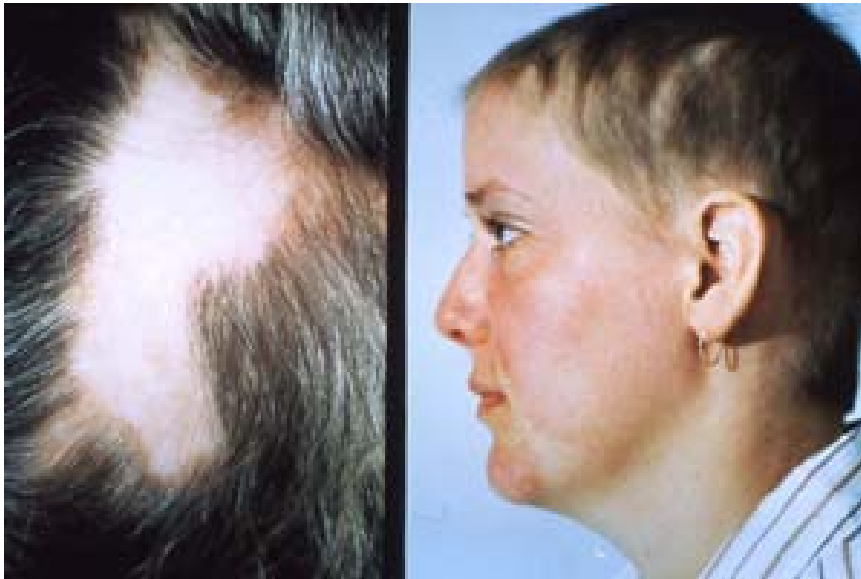Achilles tendinitis/bursitis

Ankylosing Spondylitis



Fusion sacroiliac joints, spine; limited axial mobility

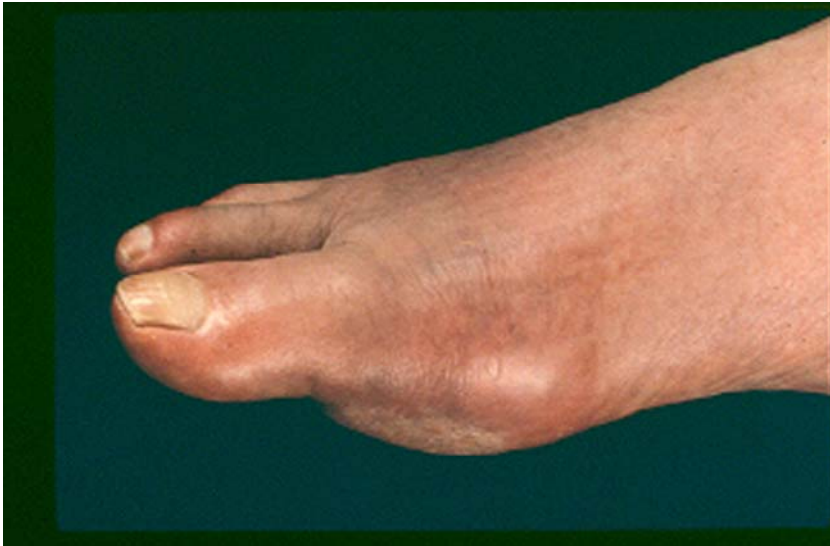Systemic Lupus Erythematosus



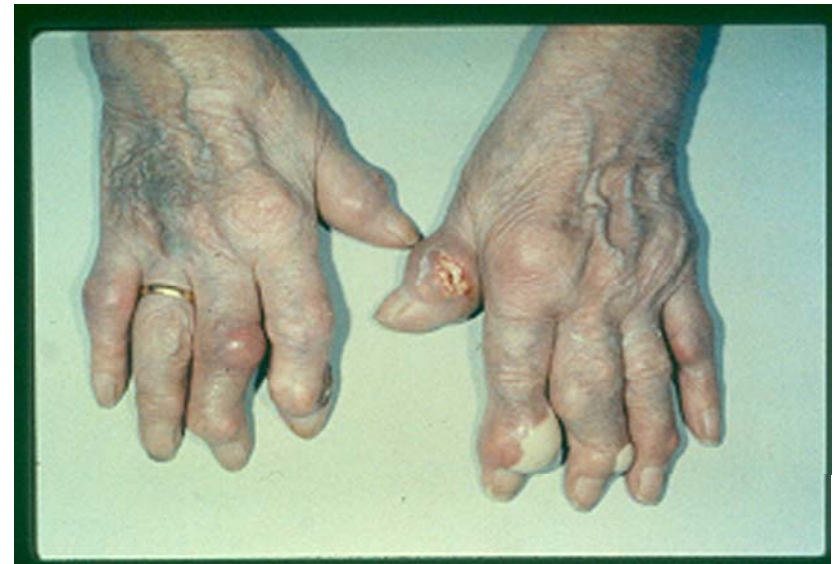Systemic Lupus Erythematosus

- ◆ **Synovitis:**
- ◆ **Polyarticular small joint predominant**
- ◆ **Transient or periodic involvement**
- ◆ **Pain levels often disproportionate for observed degree of synovitis**
- ◆ **Ischemic Pain:**
- ◆ **Raynauds (vasospasm) or vasculitis**

Gout

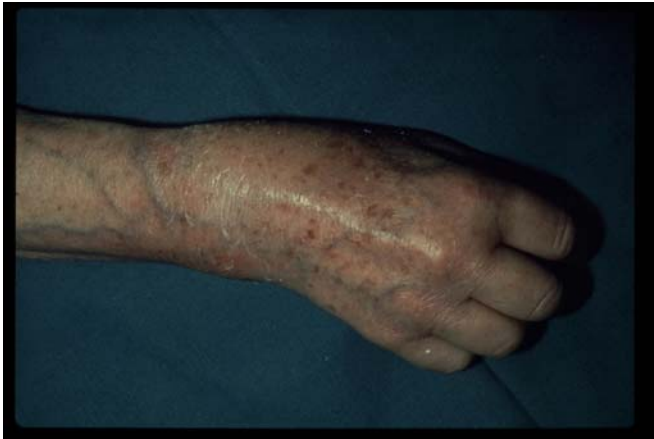

Podagra

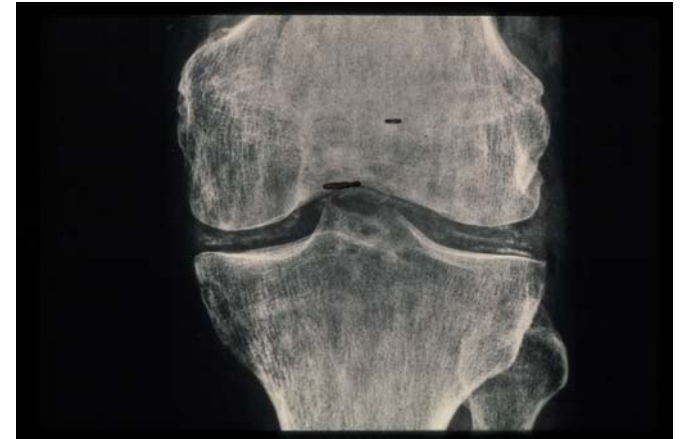

Polyarticular tophaceous gout

Pseudogout/Pyrophosphate Arthropathy

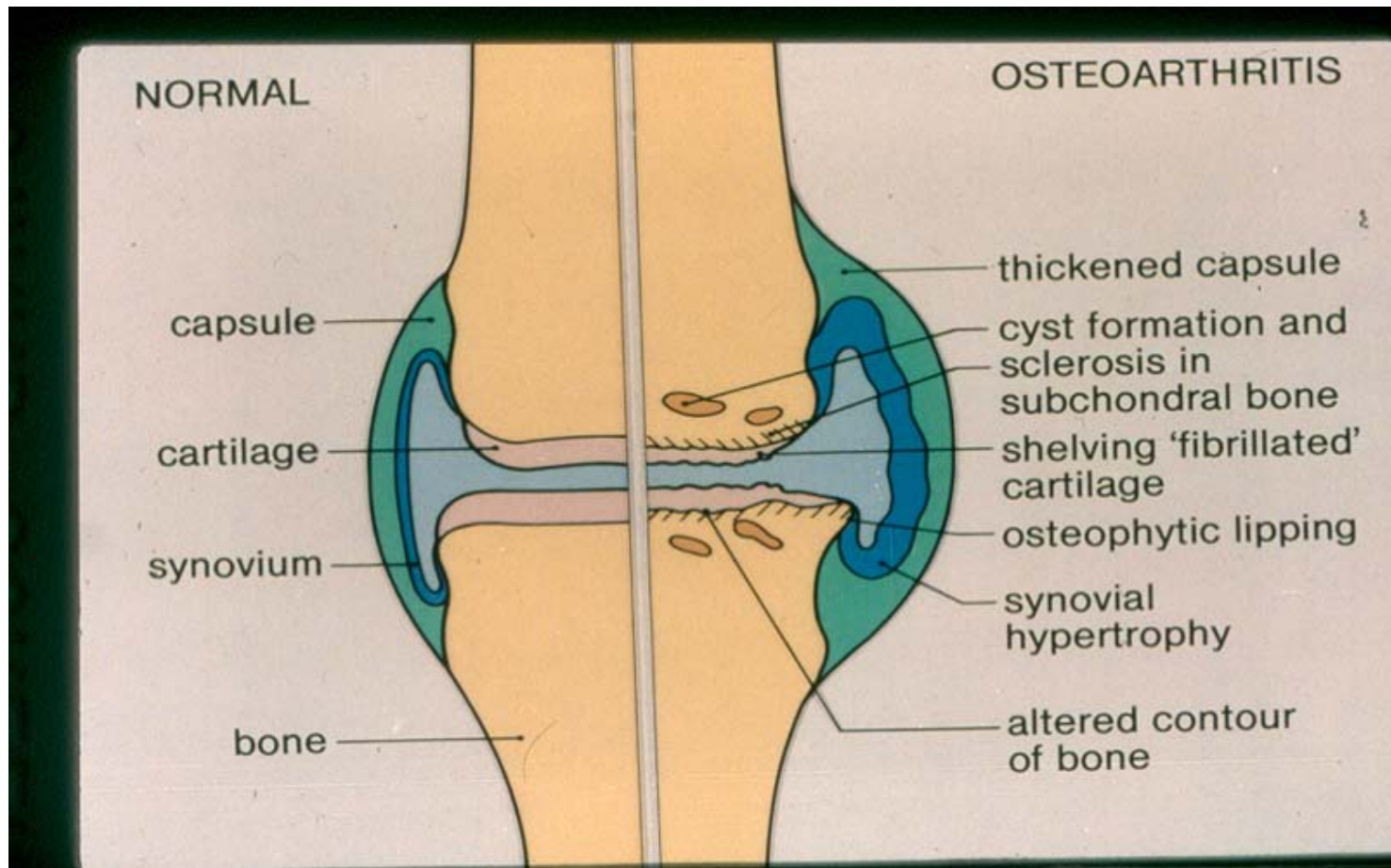


Pseudogout



Chondrocalcinosis

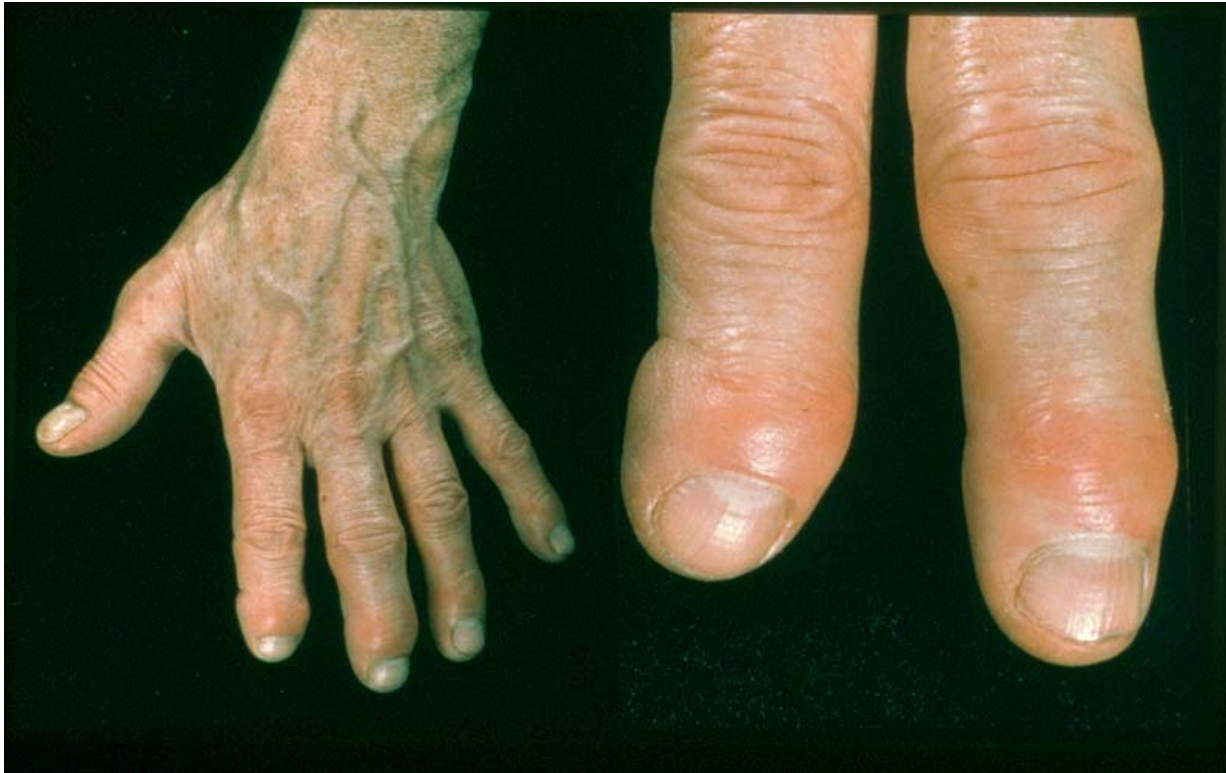Osteoarthritis



Signs and Symptoms of Osteoarthritis

- ◆ **Pain – worse on use of the joint**
- ◆ **Stiffness – mild, transient in morning or after immobility**
- ◆ **Loss of movement, range of motion**
- ◆ **Pain on movement and with use of joint**
- ◆ **Tenderness joint and periarticular**
- ◆ **Bony and soft tissue swelling**
- ◆ **Joint crepitus on movement**

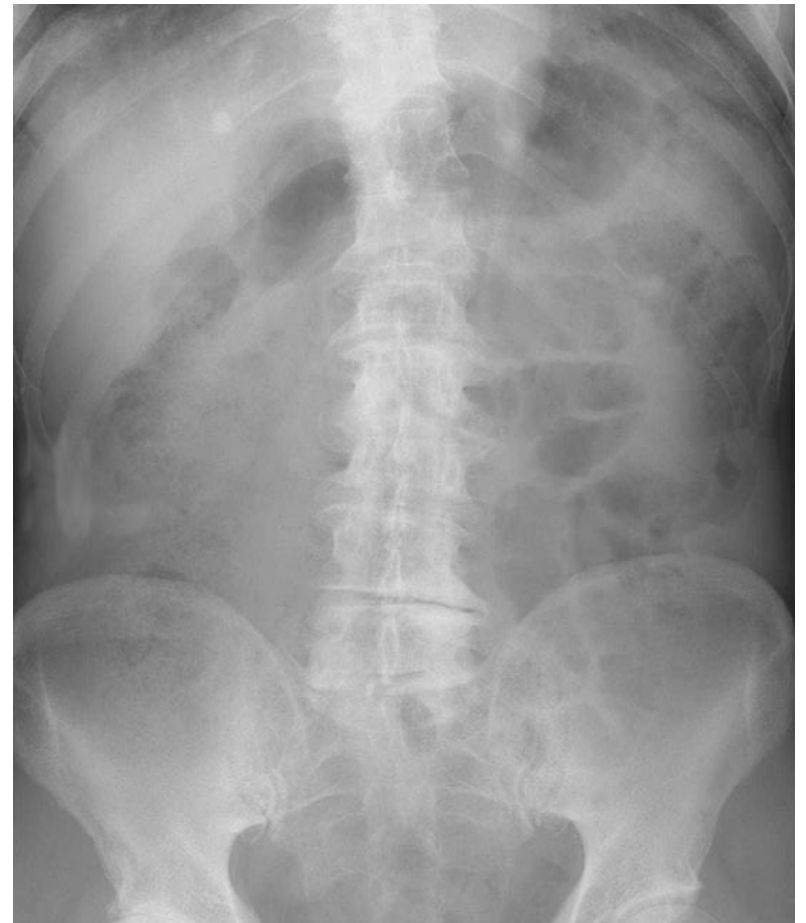
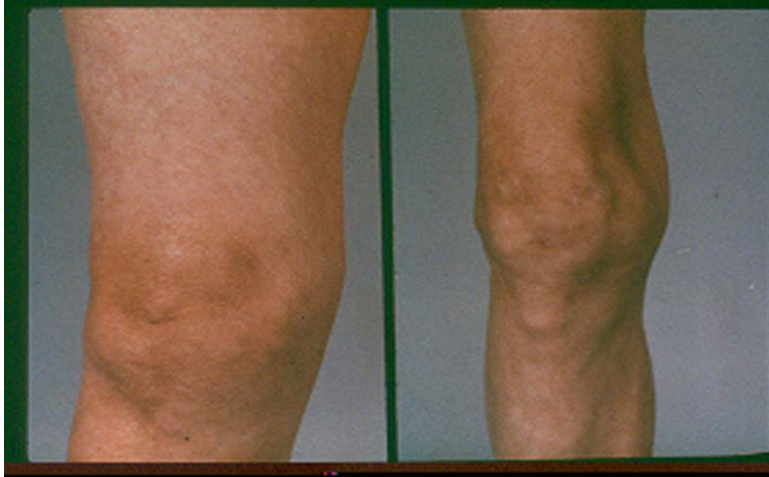
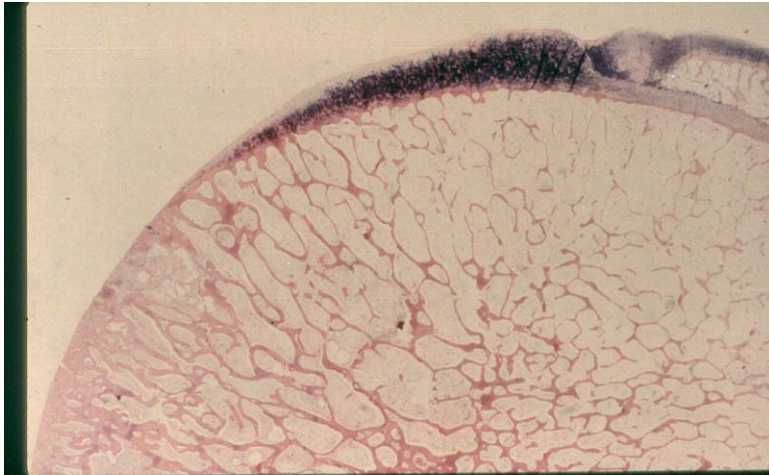
Osteoarthritis



Pain in Osteoarthritis

- ◆ **Inflammation**
- ◆ **Irritation periarticular structures – capsulitis, enthesitis (mri evidence)**
- ◆ **Intraosseous hypertension**
- ◆ **Subchondral fractures**
- ◆ **Intracapsular hypertension**
- ◆ **Mechanical Factors ie. Loose fragment**

Osteoarthritis



Pain Relief in Arthritis

- ◆ **Accurate arthritis diagnosis needed**
- ◆ **Mechanism of symptom generation elucidated**
- ◆ **Targeted and appropriate therapy can be applied**